

## PRESUMPTIVE DIAGNOSIS OF SPINA BIFIDA IN CANINE PATIENT

Amanda Lorene Rabelo<sup>1</sup>  
Felipe Gaia de Sousa<sup>2</sup>  
Suzane Lilian Beier<sup>2</sup>

### ABSTRACT

The aim of this report is to describe a presumptive diagnosis of spina bifida in a mixed breed dog, due to previous diagnostic inconsistencies. Spina bifida is an uncommon congenital anomaly characterized by poor bone formation due to incomplete closure or the absence of the dorsal arch of the vertebral structure during the process of embryogenesis. Animals with this condition may have difficulties in the locomotion process, which constantly threatens the quality and survival of those affected. Spina bifida can present itself in four different forms and degrees. A 5-month-old mixed breed dog was assisted at a veterinary clinic in Conselheiro Lafaiete/MG with difficulties in the locomotion process and previous diagnostic inconsistencies in other veterinary services. On physical examination, he had kyphosis in the thoracic region and decreased proprioceptive capacity in the hind limbs. After radiographs were taken, morphological thoracic alterations were observed in the segment between the T5 to T9 vertebrae, with duplicated spinous processes and a decrease in the dimensions of the intervertebral space. The radiographic examination suggested presumptive evidence of thoracic spina bifida due to the unavailability of the tutor to perform more sensitive exams such as tomography and magnetic resonance. Therefore, drugs for pain and neuropathic control such as gabapentin and pregabalin were prescribed, at different times, until new recommendations, which have shown therapeutic efficacy to the patient. Currently, the patient uses a wheelchair adapted for locomotion due to the loss of movement of the hind limbs, in addition to weekly physical therapy follow-up and acupuncture sessions.

**Keywords:** bone malformation, congenital alteration, locomotor alteration.

## DIAGNÓSTICO PRESUNTIVO DE ESPINHA BÍFIDA EM PACIENTE CANINO

### RESUMO

O objetivo do presente relato é descrever um diagnóstico presuntivo de espinha bífida em um cão sem raça definida, mediante inconsistências diagnósticas prévias. A espinha bífida é uma anomalia congênita incomum, caracterizada pela má formação óssea mediante o fechamento incompleto ou a inexistência do arco dorsal da estrutura vertebral durante o processo de embriogênese. Os animais portadores dessa condição podem apresentar principalmente dificuldades no processo de locomoção, o que ameaça constantemente a qualidade e a sobrevivência dos afetados. A espinha bífida pode se apresentar de quatro diferentes formas e em graus variados. Um cão sem raça definida de 5 meses foi atendido em uma clínica veterinária em Conselheiro Lafaiete/MG com dificuldades no processo de locomoção e inconsistências diagnósticas prévias em outros serviços veterinários. No exame físico, ele apresentava cifose em região torácica e diminuição da capacidade proprioceptiva nos membros posteriores. Após a realização de radiografias, foram observadas alterações morfológicas torácicas no segmento

<sup>1</sup> Department of Veterinary Medicine, Faculdade Presidente Antônio Carlos de Conselheiro Lafaiete, Minas Gerais. amandarabelomedvet@hotmail.com.

<sup>2</sup> Department of Veterinary Clinic and Surgery, Veterinary School, Federal University of Minas Gerais – UFMG, Brazil. Correspondência: fgaias@outlook.com.

entre as vértebras T5 a T9, com processos espinhosos duplicados e decréscimo nas dimensões do espaço intervertebral. O exame radiográfico sugeriu evidências presuntivas de espinha bífida torácica, em virtude da indisponibilidade financeira da tutora para a realização de exames mais sensíveis como tomografia e ressonância. Diante dos sinais clínicos e exames apresentados, prescreveu-se fármacos para controle algico e neuropático como gabapentina e pregabalina, em momentos distintos, até novas recomendações, sendo que estes demonstraram eficácia terapêutica ao paciente. Atualmente, o paciente faz uso de cadeirinha adaptada para locomoção devido à perda da movimentação dos membros posteriores, além do acompanhamento fisioterápico semanal e sessões de acupuntura.

**Palavras-chave:** alteração congênita, alteração locomotora, má formação ósea.

## DIAGNÓSTICO PRESUNTIVO DE ESPINA BÍFIDA EN UN PACIENTE CANINO

### RESÚMEN

El objetivo de este informe es describir un diagnóstico presuntivo de espina bífida en un perro sin raza definida, debido a inconsistencias diagnósticas previas. La espina bífida es una anomalía congénita poco frecuente caracterizada por una mala formación ósea debido a un cierre incompleto o la ausencia del arco dorsal de la estructura vertebral durante el proceso de embriogénesis. Los animales con esta condición pueden tener dificultades en el proceso de locomoción, lo que amenaza constantemente la calidad y supervivencia de los afectados. La espina bífida puede presentarse en cuatro formas diferentes y en diversos grados. Un perro mestizo de 5 meses de edad fue atendido en una clínica veterinaria en Conselheiro Lafaiete/MG con dificultades en el proceso de locomoción e inconsistencias diagnósticas previas en otros servicios veterinarios. Al examen físico presentaba cifosis en región torácica y disminución de la capacidad propioceptiva en miembros posteriores. Después de la toma de radiografías, se observaron alteraciones morfológicas torácicas en el segmento entre las vértebras T5 a T9, con procesos espinhosos duplicados y disminución de las dimensiones del espacio intervertebral. El examen radiográfico sugirió evidencia presuntiva de espina bífida torácica debido a la falta de disponibilidad del tutor para realizar exámenes más sensibles como tomografía y resonancia magnética. Por ello, fármacos para el control del dolor y neuropático como la gabapentina y la pregabalina fueron prescritos, en diferentes momentos, hasta nuevas recomendaciones, que han demostrado eficacia terapéutica al paciente. Actualmente el paciente utiliza una silla de ruedas adaptada para la locomoción debido a la pérdida de movimiento de los miembros posteriores, además de seguimiento semanal de fisioterapia y sesiones de acupuntura.

**Palabras clave:** malformación ósea, alteración congénita, alteración locomotora

### INTRODUCTION

Congenital spinal disorders are characterized by defects in the structure and/or function of the spine, which may or may not be of significant clinical significance (1). Among the consequences that can be observed are the difficulty and/or unfeasibility in the locomotor process, as well as problems with equilibrium and quality of life, among others. Spina bifida is a spinal anomaly characterized by bone malformation due to incomplete closure of the dorsal arch of the spine, or by lack of structure formation (2). Associated medullary and membranous protrusion or dysplasia may be present (3).

It is characterized by changes in the structure of the vertebral arch, with the possibility of being seen in the dorsal region of the arch and in the spinous processes. Among the changes

likely to occur, the presence of dorsal clefts in the vertebral arches and the inexistence or dismemberment of spinous processes are cited (2). Spina bifida may be related to the appearance of alterations in the neural tube region (4), among which are cited meningocele, meningomyelocele or myocele, due to the extensive damage present (5, 6). Although the disease can occur in several species (5), it is observed that dogs of different breeds can be affected, especially brachiocephalic breeds due to greater predisposition such as English Bulldog (7) and Pugs (1).

The etiology of this disorder is not fully understood; however, genetic, teratogenic, nutritional and racial factors have been associated with its occurrence (8). Among these are: cellular hyperplastic conditions of the dorsal tube (modifications in the union of the arches of the vertebrae and the neural tube) added to a vascular failure that restricts blood flow in the dorsal vertebral region with the possibility of functional impairment (9).

Determining the presence of spina bifida is a task that requires a lot of experience. Among the diagnostic options to confirm the presence of the condition, in addition to anamnesis, physical and laboratory tests, imaging exams are cited. Radiographs of possibly affected regions may suggest the presence of the alteration and rule out differentials, however, computed tomography (CT scan) and magnetic resonance imaging (MRI) are more confirmatory tests (2,5).

Through radiographs, it is verified that the fragmentation of the spinous portion is the most observed radiographic alteration. In addition, this disorder can be located in the thoracic region and be associated with neural tube defects, although it is an uncommon condition. In cases where there are considerable morphological deformations, especially in the lumbosacral union, they are more associated with inexistence of spinous processes, irregularities in laminar portions and in the neural tube (2). The aim of this report is to describe a presumptive diagnosis of spina bifida in a mixed breed dog, due to previous diagnostic inconsistencies.

## CASE REPORT

A 5-month-old, mixed breed, male, uncastrated, body weight of approximately 18 kg, was treated at a veterinary clinic in the city of Conselheiro Lafaiete/MG, presenting locomotor difficulties. The animal's tutor reports that he had been adopted at the beginning of December 2020 and was showing changes in locomotion. Therefore, she sought a veterinarian to proceed with the clinical evaluation of the patient, with a pelvic radiography. After the procedures described, the professional informed the tutor that there was a strong suspicion of coxofemoral luxation. Thus, the professional recommended that the case be referred to another veterinarian for corrective surgery for the suspected alteration.

The tutor contacted the professional who had been recommended for assessment and diagnostic confirmation of coxofemoral luxation dysplasia at the end of December 2020. However, after the second analysis and clinical examination, the second professional discarded the diagnosis given by the first evaluator. After this new evaluation, this professional suspected the occurrence of *myasthenia gravis* and prescribed pyridostigmine bromide 60 mg at a dose of  $\frac{1}{4}$  of the tablet every 8 hours for 8 days (3mg/kg, orally, q8h), considering the weight of the animal in this period of 5 kg. The professional reported to the tutor that the intention of prescribing pyridostigmine would be therapeutic for the treatment of the condition presented (*myasthenia gravis*).

In the final week of February 2021, the tutor reported that the animal experienced severe pain and, given the condition presented by the patient, decided to seek a third service. The choice of this new place by the tutor for evaluation was due to her displeasure with the previous appointments and because of diagnostic inconsistencies, since the animal did not show improvement. Even though pyridostigmine bromide had been prescribed, the animal still had a

symptomatic manifestation of staggering walking with intense pain during locomotion and, due to the progression of the condition, there was an absence of movement in the hind limbs. Therefore, she directed the animal to the veterinary clinic in Conselheiro Lafaiete/MG to control the episode of severe pain and for a new evaluation, in order to obtain a concise diagnosis.

In this new evaluation, the animal had normal colored mucosa, without changes in size, morphology and lymph node volume, cardiorespiratory rate according to the reference values for the species and normal body temperature. In addition, the patient had kyphosis located in the spinal region and reduced proprioception of the hind limbs. The animal did not present alterations in the other organic systems. Blood samples were collected for hematological and biochemical examination, although no noteworthy changes were detected. Causes of trauma and infectious diseases have been eliminated.

As a way to exclude possible fractures, hip dysplasia and to complement the diagnosis, it was recommended to perform a new radiograph that would allow the vertebral and pelvic assessment, which was done in the clinic of the service (Figure 1). Through the latero-lateral spinal radiography, the presence of possible alterations in the thoracic portion was noted, however inconclusively. Through the analysis of the ventrodorsal radiograph of the pelvic region, the hypothesis of occurrence of hip dysplasia suspected by the first professional was discarded, due to the presence of deep and smooth acetabulum, round femoral head and well coupled to the acetabulum (Figure 1).

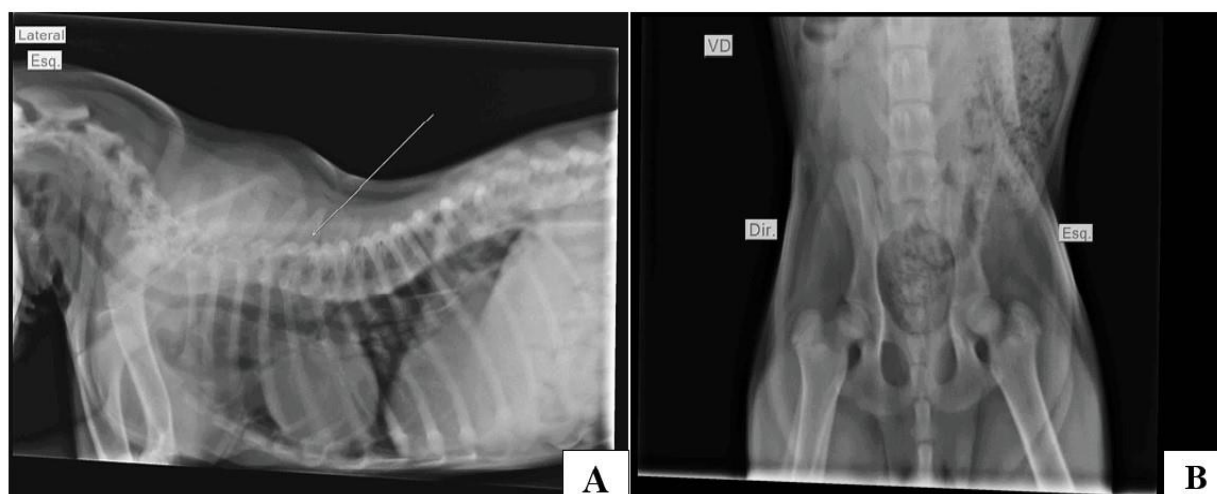

Figure 1. Radiographs of the vertebral and pelvic region of the animal referred to in this case. (A) Left lateral view of the spine with visualization of cervical and thoracic vertebral structures and a part of the lumbar region. The presence of kyphosis and possible narrowing of the vertebral bodies are observed. Note at the arrowhead, a vertebral structure of inconclusive aspect in the thoracic region, close to the intervals between vertebrae T4 to T10 (arrowhead). (B) Ventrodorsal projection (VD) of the pelvic region with visualization of bone structures within the common radiographic pattern, with deep and smooth acetabulum, as well as a round and well-coupled femoral head to the acetabulum. It is noteworthy that the patient's misaligned position during the exam may suggest false diagnoses.

Given the condition of diagnostic inconsistency observed in the latero-lateral spinal radiographs and in association with the severity of the patient's condition, the team of this veterinary clinic in Conselheiro Lafaiete, chose to indicate the animal to a neurologist. The suggestion of a specialized consultation was due to the set of symptoms presented by the animal, the severity and progression of the condition, in addition to making it possible to rule out more

serious neurological disorders. Furthermore, due to the diagnostic inconsistency experienced by the spinal radiography, the specialist was asked to perform a new radiographic examination, in order to allow a better analysis and visualization of the possibly affected structures. For the treatment of the painful manifestation, 1 capsule of gabapentin 180 mg, twice a day, orally – PO (10 mg/kg, q12h) was prescribed for an indefinite period until new recommendations, and this drug was remanipulated in a partner laboratory of the clinic. According to the tutor, the medicine provided great help to improve the animal's painful condition.

In the second week of March 2021, the patient was evaluated by a neurologist and new radiographs of the spine were taken, focusing on the evaluation of the thoracic region (right latero-lateral position). The radiographic report showed the following information: thoracic vertebral morphological alteration in the region comprised of vertebrae T5, T6, T7, T8, and T9, with an aspect of duplicity of the spinous processes associated with a generalized reduction of the intervertebral spaces between these vertebrae; it is observed the cardiac silhouette displaced in the cranial direction and protrusion of a portion of the cranial pulmonary lobe to the outside of the thoracic cavity towards the cervical region; other structures without noteworthy alterations (Figure 2). It should be noted that the examination was performed without the use of analgesia and/or sedation, which made it difficult in parts to obtain an appropriate radiographic position.

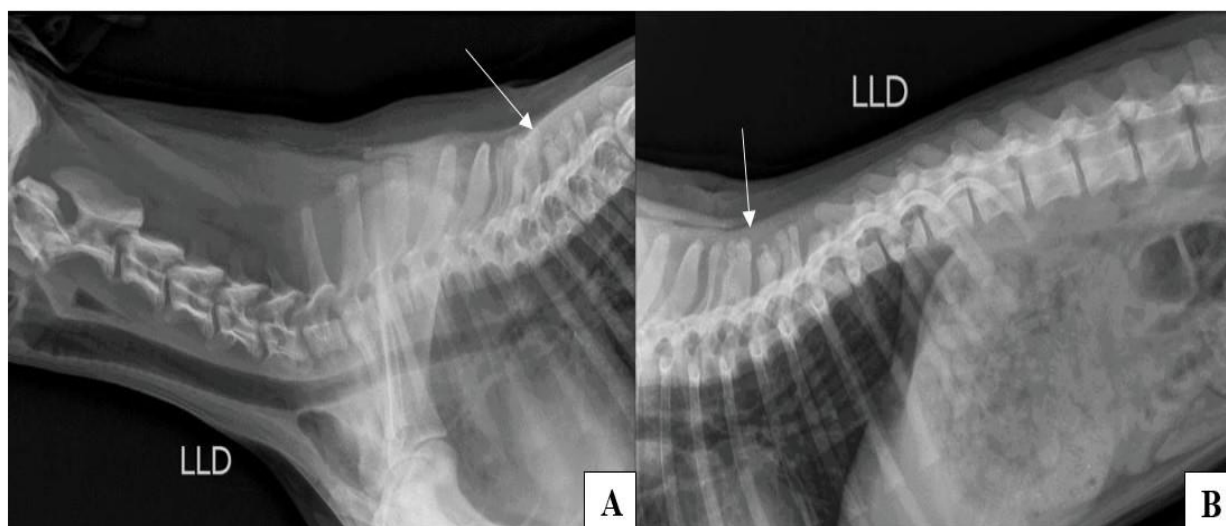


Figure 2. Latero-lateral radiographs of the patient's spine with a focus on the thoracic segment. (A) Right latero-lateral (LLD) position that includes the visualization of the entire cervical segment and part of the thoracic portion. Visualization of morphology change in the thoracic segment, in the vertebral region comprised by the T5, T6, T7, T8 and T9 vertebrae, associated with a duplicated aspect of the spinous processes and with a reduction in the intervertebral space between them (arrowhead). (B) Right latero-lateral projection with visualization of the final thoracic portion and beginning of the lumbar segment. Note the same vertebral segment (T5 – T9) with morphological changes, intervertebral narrowing and duplicity of spinous processes (arrowhead).

Given the condition observed through radiographic evidence and the animal's locomotor difficulty, strong indications of the presumptive diagnosis of thoracic spina bifida were observed. The definitive and conclusive diagnosis of spina bifida could not be determined due to the absence of more specific imaging tests such as computed tomography and magnetic resonance imaging. These exams were not performed by the tutor due to her financial condition,

although they were suggested. The neurologist responsible for the care informed the tutor that the gabapentin would be discontinued and that a new drug would be prescribed. The new drug prescribed was pregabalin 75 mg for pain control, with a neuropathic aspect, at a dose of 1 tablet by PO, every 12 hours, for continuous use. It was also recommended to start physical therapy activities at weekly intervals and alternative therapy through acupuncture.

Currently, the animal is approximately 30 kg, 11 months old, no longer uses pregabalin 75 mg and no other drug for pain control of neuropathic origin. The use of a specific wheelchair for locomotion is still necessary due to the loss of functionality of the hind limbs. Furthermore, the use of acupuncture and physiotherapy still remain with the aim of promoting quality of life, helping the animal during the daily locomotion processes and to strengthen the body's musculature.

A major limitation of the present case report was the absence of a computed tomography scan. Computed tomography is considered the gold standard test for diagnosing spina bifida. In this patient, the examination would be very useful to confirm the presence of the vertebral alteration. However, for financial reasons, the tutor preferred not to perform the tomography, making a more accurate diagnostic determination unfeasible, although this was a recommendation of the professionals responsible for the case.

## DISCUSSION

According to Miranda et al. (3), spina bifida is considered a vertebral alteration, but specifically in regions involving the vertebral arches, being caused by formation disorders during the embryonic process. In a study conducted by Bertram et al. (10), 10% of the animals evaluated presented spina bifida. Animals with this congenital condition, as mentioned above, may show variability in degree and symptomatology. Depending on the level of involvement and magnitude of the disease, the presence of lesions in organs of the nervous system can be observed (3). According to Wilson et al. (11), the degree of malformation in the vertebral arch region dictates the chance of consequences such as protrusions and/or dysplasia in the medulla and meninges, these described by Miranda et al. (3).

For Taylor (12), spina bifida can be observed in any region of the spine, although its largest sample is described in the lumbar caudal and lumbosacral segments. The prevalence of the region of most common occurrence of the disease for Bertram et al. (10) was 50% in the third sacral vertebra, followed by 37.5% and 12.5% in the second and first sacral regions, respectively. In the case reported here, the animal presented spina bifida in the thoracic region, more specifically in the region between the T5, T6, T7, T8 and T9 vertebrae, this form also seen and described by Miranda et al. (3). Shamir et al. (7) reported the occurrence of spina bifida in the region of the seventh lumbar vertebra to the sacral segment in a 2-month-old female English Bulldog dog. According to Widmer and Thrall (2), these dysfunctions when they occur in the thoracic portions and with involvement of the neural tube are considered less frequent.

The clinical signs presented by the animal and reported by the tutor were difficulties in locomotion, in keeping upright and severe pain, although over the months since the initial care, a loss of locomotor capacity in the hind limbs has been noticed. After clinical evaluation, the complaints presented by the tutor were confirmed, as well as a picture of thoracic kyphosis and decreased proprioceptive capacity in the pelvic. Miranda et al. (3) also report the presence of kyphosis in a fetus with spina bifida and the difficulty in walking was also described by Gomes et al. (13). According to Taylor (12), animals with spina bifida present clinical manifestations from birth, can vary in "hind limb paresis in the lower motoneuron region, fecal and urinary incontinence, loss of perineal sensitivity and decreased tone anal sphincter".

The diagnosis of spina bifida can be obtained through data obtained during the anamnesis, physical, laboratory and imaging exams (8). The information described by the tutors during the

time of patient assessment will be useful to know the period in which the tutor observed the onset of symptoms, as well as what signs the animal presents. The physical examination will allow the veterinarian to determine possible locations for the occurrence of changes, as well as raise hypotheses about possible diagnoses. Animals with this congenital condition may present relevant laboratory alterations depending on the clinical picture, although these provide few data that contribute to the diagnostic determination.

An important diagnostic tool is imaging tests such as radiographs, MRIs, myelographies and CT scans (8,14). However, each of these options above presents varying degrees of sensitivity and specificity for detecting spina bifida conditions and, therefore, the diagnosis made in association may be a desirable option, as its use was described by Arias et al. (8). Radiographs, whether in latero-lateral and ventrodorsal projections, offer great indications of the presence of a spine, although they cannot offer further conclusions about the condition due to its low sensitivity and specificity. CT scans and MRIs, the latter considered as the gold standard, are more specialized tools to help classify and determine the presence of the condition as well as possible damage to adjacent organs (2).

Spina bifida can be classified into several types, the categorization being based on human medicine. The described forms of this condition are: occult type, spina bifida associated with meningocele, the form related to myelocele, and the condition linked to meningomyelocele/myelomeningocele. The hidden form is characterized by the presence of the disease, although there is no involvement of nerve segments. The one associated with meningocele is classified this way due to the protrusion of the meninges and the conditions associated with myelocele are due to displacement of the spinal tissue, both originating from the vertebral opening. Finally, the type of spina bifida related to meningomyelocele/myelomeningocele are categorized in this way due to the protrusion of tissues and meninges (8,15).

In the present report, the diagnosis of spina bifida could be presumptively given in conjunction with the clinic presented, one in which only radiographic examinations of the vertebral segments were performed, focusing on the thoracic region. Computed tomography and magnetic resonance examinations were not performed in the present report. The price and availability of places that carry out more specific tests for detection were conditions described by the tutor for not carrying out these tests. The clinic responsible for the case and the specialist described above, guided the tutor and explained the benefits that the tests above could help in providing greater detail of the condition. Furthermore, given the financial condition of the tutor, it was not possible to establish the classification of the type of spina bifida present in this case.

For Taylor (12), there is no effective treatment for spina bifida. Surgical corrections can be made depending on the condition presented, as the case described by Koslov & Bhattarai (14) when performing a laminectomy in a 1-year-old male dog with occult spina bifida. In the present report, given the symptoms presented by the patient, it was necessary to introduce some medications with the aim of controlling pain, with a chronic and/or neuropathic aspect, such as gabapentin and pregabalin. According to Romeu et al. (16), gabapentin and pregabalin act with the intention of inhibiting calcium channels at the neuronal level, which prevents the release of various groups of neurotransmitters”.

The prescription of gabapentin at a dose 10 mg/kg, q12h, PO, was motivated to manage and treat pain of neuropathic origin, which according to the tutor was effective for pain control in the patient. The recommended dose of gabapentin is 10-15 mg/kg, orally, 1 or 2 times a day for Kaminishi & Hirano (17), and 2.5-10 mg/kg (maximum limit of 15 mg/kg), PO, 1-3 times a day for Plumb (18), with the dose prescribed to the patient within the ranges described. The use of gabapentin as a therapeutic option in neuropathic cases was also described by Sontag et al. (19) after use in a female dog with severe neuropathy.

After the neurologist's evaluation, gabapentin was replaced by 1 tablet of 75 mg of pregabalin q12h for continuous use. The recommended dose of pregabalin is 3-4 mg/kg, q12h, orally (18,20). The dose prescribed to the animal was within the suggested range. The replacement of medication can be explained by the specialist's experience with the use of the drug, as according to Sontag et al. (18) both can be used for neuropathic management. For Andrade (21), the pharmacological half-life of pregabalin is greater than that of gabapentin. According to a study conducted by Toth (22), the exchange of gabapentin for pregabalin provided quality of life and increased pain relief in human patients. For Salazar et al. (23) and Kukanich (24), pregabalin improves quality of life and has high oral bioavailability in animals that use it. In a study conducted by Sanchis-Mora et al. (25) pregabalin was effective for the management of neuropathic pain as well as for dogs with Chiari Syndrome and/or syringomyelia associated with neuropathic pain, significantly reduced hyperalgesia and provided mild sedation.

For Arias et al. (8), the difficulties observed in defining the diagnosis and establishing possible causes, the therapies that provide control and resolution of the problem are few in number. Thus, the prognosis of this congenital condition is usually reserved, tending to unfavorable. However, the patient in the present report adapted well to the prescribed medications and the situation to which he was imposed, although he lost movement in his hind limbs and needed locomotor assistance with an adapted wheelchair. Furthermore, the physiotherapy and acupuncture sessions requested by the neurologist are initially promoting the improvement of the animal's muscular and ambulatory capacity. Thus, it is noteworthy that in cases where there are patients with locomotor difficulties, with changes in the ability to stand upright, especially in younger patients, the diagnostic hypothesis of spina bifida should be investigated.

## ACKNOWLEDGEMENTS

Clinical team of Pronto Socorro Veterinário – Conselheiro Lafaiete/MG, Brazil.

## REFERENCES

1. Ryan R, Gutierrez-Quintana R, Ter Haar G, De Decker S. Prevalence of thoracic vertebral malformations in French Bulldogs, Pugs and English Bulldogs with and without associated neurological deficits. *Vet J.* 2017;221:25-9. doi: 10.1016/j.tvjl.2017.01.018.
2. Widmer WR, Thrall DE. Canine and feline vertebrae. In: Thrall DE, editor. *Textbook of veterinary diagnostic radiology.* 7th ed. St. Louis: Saunders; 2018. p. 248-69.
3. Miranda DFH, Ferraz MS, Azevedo JWC Jr, Fortes EAM, Conde AM Jr, Carvalho MAM. Spina bifida in newborn cat: case report. *Semin Cienc Agrar.* 2011;32:1975-80. doi: 10.5433/1679-0359.2011V32N4SUP1P1975.
4. Thomas ZM, Podadera JM, Donahoe SL, Foo TSY, Weerakoon L, Mazrier H. Neural tube defects in four Shetland sheepdog puppies: clinical characterization and computed tomography investigation. *Aust Vet J.* 2020;98(7):312-8. doi: 10.1111/avj.12949.
5. Lempek MC, Bordelo J, Veado JC, Dias MIR. Espinha bífida em um cão sem raça definida - relato de caso. *Rev Bras Med Vet.* 2016;38(3):211-3.



6. Thrall DE, Robertson ID. Atlas of normal radiographic anatomy and anatomic variants in the dog and cat. 2nd ed. Saint Louis: Saunders; 2016.
7. Shamir M, Rochkind S, Johnston D. Surgical treatment of tethered spinal cord syndrome in a dog with myelomeningocele. *Vet Rec.* 2001;148(24):755-6. doi: 10.1136/vr.148.24.755.
8. Arias MVB, Marcasso RA, Margalho FN, Sierra S, Oliveira M, Oliveira RR. Spina bifida in three dogs. *Braz J Vet Pathol.* 2008;1(2):64-9.
9. Moore KL, Persaud TVN, Torchia MG. Embriologia clínica. 2a ed. Rio de Janeiro: Guanabara Koogan; 2013.
10. Bertram S, Ter Haar G, De Decker S. Congenital malformations of the lumbosacral vertebral column are common in neurologically normal French Bulldogs, English Bulldogs, and Pugs, with breed-specific differences. *Vet Radiol Ultrasound.* 2019;60(4):1-9. doi: 10.1111/vru.12753.
11. Wilson JW, Kurtz HJ, Leipold HW, Lees GE. Spina bifida in the dog. *Vet Pathol.* 1979;16(2):165-79. doi: 10.1177/030098587901600202.
12. Taylor SM. Disorders of spinal cord. In: Nelson RW, Couto CG, editors. *Small animal internal medicine.* 6th ed. Saint Louis: Elsevier; 2020. p. 1130-56.
13. Gomes CAR, Sampaio LM, Anacleto TP, Akamatsu A, Malagó R. Espinha bífida associada à síndrome do cão nadador: relato de caso. *Rev Cient Universitas.* 2018;5(2):11-9.
14. Koslov N, Bhattarai B. Spina bifida occulta and surgical treatment in a Yorkshire terrier. *J Small Anim Pract.* 2019;60(10):636. doi: 10.1111/jsap.13053.
15. Bouma JL. Congenital malformations of vertebral articular processes in dogs. *Vet Clin North Am Small Anim Pract.* 2016;46(2):307-26. doi: 10.1016/j.cvsm.2015.10.006.
16. Romeu R, Gorczak R, Valandro MA. Analgesia farmacológica em pequenos animais. *Pubvet.* 2019;13(11):1-12. doi: 10.31533/pubvet.v13n11a459.1-11.
17. Kaminishi APS, Hirano LQL. Uso de gabapentina no controle da dor em pequenos animais: revisão de literatura. *Vet Foco.* 2017;14(2):29-35.
18. Plumb DC. *Plumb's veterinary drug handbook.* 7th ed. Stockholm: Wiley-Blackwell; 2011.
19. Sontag SC, Belletini ST, Tramontin RS, Conti JB, Pachaly EMV, Quessada AM, et al. Utilização de gabapentina para manejo clínico de dor neuropática em cães - relato de caso. *Arq Cienc Vet Zool UNIPAR.* 2017;20(4):221-31. doi: 10.25110/arqvet.v20i4.2017.6401.
20. Viana FAB. *Guia terapêutico veterinário.* 4a ed. Lagoa Santa: Editora Cem; 2019.
21. Toth C. Substitution of gabapentin therapy with pregabalin therapy in neuropathic pain due to peripheral neuropathy. *Pain Med.* 2010;11(3):456-65. doi: 10.1111/j.1526-4637.2009.00796.x.

22. Andrade SF. Manual de terapêutica veterinária: consulta rápida. Rio de Janeiro: Roca; 2017.
23. Salazar V, Dewey CW, Schwark W, Badgley BL, Gleed RD, Horne W, et al. Pharmacokinetics of single-dose oral pregabalin administration in normal dogs. *Vet Anaesth Analg*. 2009;36(6):574-80. doi: 10.1111/j.1467-2995.2009.00486.x.
24. Kukanich B. Outpatient oral analgesics in dogs and cats beyond nonsteroidal antiinflammatory drugs: an evidence-based approach. *Vet Clin North Am Small Anim Pract*. 2013;43(5):1109-25. doi: 10.1016/j.cvsm.2013.04.007.
25. Sanchis-Mora S, Chang YM, Abeyesinghe SM, Fisher A, Upton N, Volk HA, et al. Pregabalin for the treatment of syringomyelia-associated neuropathic pain in dogs: a randomised, placebo-controlled, double-masked clinical trial. *Vet J*. 2019;250:55-62. doi: 10.1016/j.tvjl.2019.06.006.

**Recebido em: 05/12/2022**

**Aceito em: 13/04/2023**