

AUTOHEMOTHERAPY AT ACUPUNCTURE POINTS POST ORCHIECTOMY SURGERY IN CART HORSES- EIGHT CASES REPORT

Pierre Barnabé Escodro¹
Jean G. Fernandes Joaquim²
Tobias M. de Albuquerque Mariz³
Aline Saraiva de Oliveira⁴
Lucineia Oliveira Escodro⁵
Elvan Nascimento Santos Filho⁶
José Valmir Tenório Ferreira Junior⁷
Juliana Oliveira Bernardo⁸

ABSTRACT

In Northeastern of Brazil, due to local financial and cultural problems, the orchiectomies in cart horses is often done by lay people, with high rates of mortality and suffering to the animals. The aim of this article was to evaluate the use of the autohemotherapy post orchiectomy surgery at acupuncture points in eight cart horses, as a substitute technique for the use of analgesics and antibiotics, in places where such medical drugs are not available. None of the animals has shown fever, appetite change or significant change in the physiological parameters during the post surgical evaluation. Autohemotherapy at acupuncture points in the equine orchiectomies postoperative proved to be effective.

Keywords: cart horses, orchiectomy, postoperative, hemo-acupuncture

AUTO-HEMOTERAPIA EM PONTOS DE ACUPUNTURA NOS PÓS-OPERATÓRIOS DE ORQUIECTOMIAS DE EQUINOS CARROCEIROS- RELATO DE OITO CASOS

RESUMO

Na região Nordeste do Brasil, devido às dificuldades financeiras e culturais, as orquiectomias em cavalos de tração carroceiros são realizadas por leigos, com altos índices de mortalidade e sofrimento dos animais. O objetivo deste artigo foi avaliar a utilização da auto-hemoterapia em pontos de acupuntura nos pós-cirúrgicos de orquiectomias de equinos utilizados em carroça, na substituição da terapia convencional com analgésicos e antibióticos, em locais onde a utilização dos fármacos não é possível. Durante a avaliação dos casos, nenhum dos animais apresentou febre, mudança de apetite ou alterações significativas nos parâmetros fisiológicos. A auto-hemoterapia em pontos de acupuntura mostrou-se satisfatória em pós-operatórios de orquiectomias em equinos.

Palavras-chave: cavalos carroceiros, orquiectomia, pós-operatórios, hemo-acupuntura

¹ Professor Adjunto do Curso de Medicina Veterinária- Universidade Federal de Alagoas (UFAL)

² Professor Drº do Instituto Bioethicus-Botucatu-SP

³ Professor Adjunto de Equinocultura e Anatomia dos Animais Domésticos- Curso de Zootecnia-UFAL

⁴ Graduanda Curso de Medicina Veterinária e Bolsista de Desenvolvimento Institucional-UFAL

⁵ Técnica em Enfermagem e Biomédica Pesquisadora do GRUPEQUI-UFAL

⁶ Médico Veterinário do Curso de Medicina Veterinária-UFAL

⁷ Graduando Curso de Medicina Veterinária e Bolsista Permanência Institucional-UFAL

⁸ Graduando Curso de Medicina Veterinária e Bolsista de Iniciação em Inovação Tecnológica CNPq

AUTOHEMOTERAPIA EN PUNTOS DE ACUPUNTURA EN EL POSTOPERATORIO DE ORQUIECTOMÍAS EN EQUINOS DE TRACCIÓN DE CARROZA- REPORTE DE OCHO CASOS

RESUMEN

En la región noreste de Brasil, debido a las dificultades financieras y culturales, las orquiectomías de equinos de tracción de carroza son hechas por prácticos, con altas tasas de mortalidad y sufrimiento de los animales. El objetivo del presente trabajo fue evaluar la utilización de la autohemoterapia en puntos de acupuntura en el postoperatorio de orquiectomías de caballos de carroza, como sustituto a la terapia con analgésicos y antibióticos, en lugares donde el uso de las drogas no es posible. Durante la evaluación de los casos, ninguno de los animales mostró fiebre, cambios en el apetito o cambios significativos en los parámetros fisiológicos. La autohemoterapia en puntos de acupuntura fue satisfactoria en el postoperatorio de orquiectomías en equinos.

Palabras clave: caballos de tracción de carroza, orquiectomía, postoperatorios, hemoacupuntura

INTRODUCTION

The Alagoas State, Northeastern of Brazil, has one of the lowest indexes of human development in Brazil. So, the cart horses used by people in that area are the financial source for many families, reaching in some municipalities 5 % of the economically active population (1).

The orchietomies of those animals are indicated to improve the behavior, to avoid transmission of genetic characteristics not desirable to the descendants and to limit some infect-contagious disease progression (2, 3). Due to financial and cultural problems, many owners avoid the surgical procedure done by certified veterinarians. So, many of these surgical procedures are done by lay people, without antisepsis and post surgical therapy, with high rates of mortality and suffering to the animals.

In order to demonstrate and teach the technique of orchietomy in standing position in equine cart horses from Alagoas State in practical classes for the discipline of Veterinary Surgical Technique and enable the surgery at a low cost for the poor community, this paper proposed the evaluation of the use of the postoperative technique of autohemotherapy at acupuncture points as a substitute medical therapy for the use of analgesics and antibiotics, leading to exemption of the surgical cost and promoting welfare in places where such medical drugs are not available.

CASES REPORT

This paper reports the cases of eight cart horses, without specific breed, with age ranging from 3 to 10 years, and weigh from 190 to 358kg, which after clinical exam were submitted to orchietomy using emasculator in standing position, under neuroleptic analgesia with acepromazine (0,05mg/kg) and after fifteen minutes xylazine (0,5mg/kg), both intravenously (IV), and local analgesia (lidocaine), as described by Finger et al. (2) and Lopes, Escobro and Silva (3). The only treatment done post surgery was autohemotherapy at acupuncture points immediately after the surgical procedure, followed by local dressings at surgical site. The volume used was 30ml of whole blood, collected from the left jugular vein, with puncture done with a 40mmX1,2mm needle and immediately administered with a 30mmX0,8mm

needle in four points: 10ml intramuscular, caudal to triceps brachial muscle, at an acupuncture point nominated as Immunity Point (IP); 5ml at 5cm lateral to the 2nd and 3th lumbar vertebra, at an acupuncture point nominated Bladder 23 (BI23); 5ml in between the Achilles tendon and the external tibial malleolus, at an acupuncture point nominated Bladder 60 (BI60) and 10ml in a depression between the anus and the tail, at an acupuncture point nominated Governador Vessel 01 (GV01). The points were chosen due to its properties on immunological system, genitourinary disturbance, lombossacral pain, edema, genital function and anti-inflammatory effects, according to Chinese Traditional Medicine theory (4-9).




Fig. 1. A-Location of acupoints used: Immunity Point (IP), Bladder 23 (BI23), Bladder 60 (BI60) and Governador Vessel 01(GV01),in the lower right corner. B-Equine orchietomy using emasculator in standing position

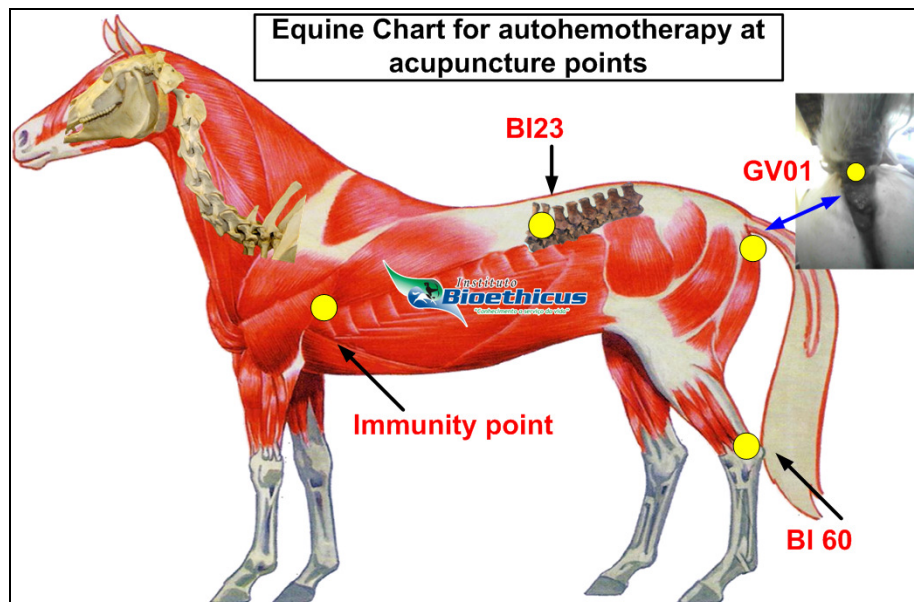


Fig. 2. Equine Chart for autohemotherapy at acupoints points post orchietomy surgery in cart horses

All patients were admitted at the vet school barn for the first 72h and been evaluated at every 8h in relationship to vital signs, appetite and surgical wound aspect. The vital signs evaluated were: heart rate (bpm), respiratory rate (breaths/ min), temperature (T°C), color of the oral mucosa and capillary refill time (CRT). Appetite was monitored through the ingestion of 1 kg of commercial feed every 8h, being: A- excellent appetite (ingestion of the total

quantity offered); B- good (ingestion of 50 to 90%); C-moderate (intake of 20 to 50%) and D- inhibited appetite (intakes below 20%). Surgical wound aspect was classified as follows: I- normal healing; II-healing with edema; III- healing with edema and mucus secretion and IV- healing with edema and purulent discharge. The surgical dressing was changed and checked every 12h through douche, povidone iodine and repellent spray. After this, all animals were evaluated every 7 days for 4 weeks.

Analyzing the signs it was observed that eight horses remained with normal color of the oral mucosa throughout the evaluated period; in relation of the appetite all remained in the A classification. Evaluating the surgical wound aspect, all animals showed the I or II classification, which is expected in post-operatives of horses orchiectomies. Only one horse was presented grade III with forty-eight hours post-procedure, possibly associated with difficulty of carrying out the dressing by aggressive behavior, returning to grade I in seven days.

The CRT of all the animals was between one and two seconds, which is considered normal for the species. The parametric parameters (bpm, hearth/min and T°C) were recorded and the distribution of response variables was analyzed and a descriptive statistic was produced. Linear Models for repeated measures (10) were used to compare the average of the parameters between the periods studied. Tukey's method was used to adjust the P-value resulting from the multiple comparisons between moments and the statistical significance was defined as $P < 0.05$. There was a difference between the averages, but there was no significant change ($P > 0.05$), identifying that no animal had tachycardia, tachypnea or hyperthermia related to the lack of post-surgical therapy such as pain killers or antibiotics.

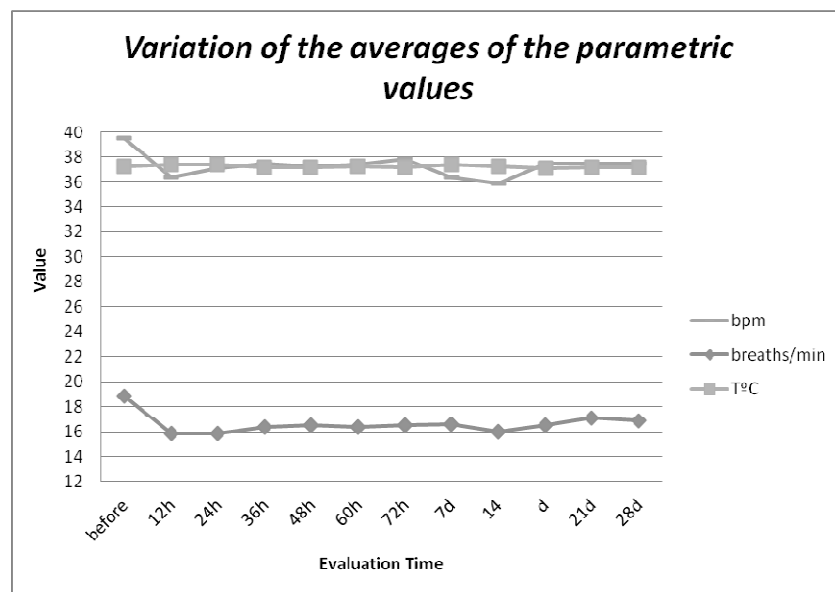


Fig. 3. Variation of the averages of the parametric values assessed during the reported cases. The changes were not statistically significant ($P > 0.05$).

DISCUSSION AND CONCLUSION

The orchiectomies in standing position under neuroleptoanalgesy and local anesthesia did not present any complications during surgery, being considered a satisfactory procedure for submission of the animals for such approach.

Autohemotherapy at acupuncture points in the postoperative of equine orchiectomies showed to be effective, without any complication or sign of interference in the welfare of animals, though there is a necessity of more studies comparing the physiological response of

equines submitted to autohemotherapy at acupuncture points in relationship to others submitted to conventional antibiotics and anti-inflammatory after post surgical procedure, validating this protocol in equine postoperative routine on communities with poor veterinary medical approach.

REFERENCES

1. Escodro PB, Tonholo J, Fernandes T, Oliveira CF, Bernardo JO, Oliveira AS, et al. Projeto carroceiro em Alagoas: empreendedorismo e inovação no ensino de medicina veterinária e potencial multidisciplinar-resultados preliminares. *Rev Bras Med Equina*. 2010;30:26-30.
2. Finger MA, Dornbusch PT, Bonfá AF, Dornbusch LPTC, Deconto I, Barros Filho IR. Comparison of two techniques in equine orchietomy, employed in the instruction of the veterinary surgical technique. *Arch Vet Sci*. 2011;6:53-9.
3. Lopes PFR, Escodro PB, Silva RH. Estudo retrospectivo de orquiectomia em estação com uso do emasculador em 52 cavalos: 2002-2008. In: *Anais do 4º Simpósio Internacional do Cavalo Atleta; 2009, Belo Horizonte*. Belo Horizonte: Universidade Federal de Minas Gerais; 2009. p.26-8.
4. Cain M, Escodro PB, Luna SPL, Joaquim JGF, Hunziker ARO. Equine protozoal Myeloencephalitis: How predictable is the diagnosis with Acupressure? In: *Proceedings of 29th International Congress on Veterinary Acupuncture; 2002, Santos*. Fort Collins: IVAS; 2002. p.315-9.
5. Lade A. *Acupuncture points: images & functions*. Seattle: Eastland Press; 1989.
6. Scognamillo-Szabó MVR, Bechara GH. Acupuntura: histórico, bases teóricas e sua aplicação em medicina veterinária. *Cienc Rural*. 2010;40:491-500.
7. Pittler MH, Ernst E. Effectiveness of Acupuncture in veterinary medicine: systematic review. *J Vet Intern Med*. 2006;20:480-8.
8. Skarda RT, Tejwani GA, Muir WW. Cutaneous analgesia, hemodynamic and respiratory effects, and B-endorphin concentration in spinal fluid and plasma of horses after acupuncture and electroacupuncture. *Am J Vet Res*. 2002;63:1435-42.
9. Xie H, Preast V. *Xie's veterinary acupuncture*. Oxford: Blackwell; 2007.
10. SAS Institute. *SAS/STAT. User's Guide. Version 9.2*. Cary, NC: SAS Institute Inc.; 2009.

Recebido em: 06/07/12

Aceito em: 17/09/12