

## ATROPHY OF THE SUPRA AND INFRASPINATUS MUSCLES DUE TO INJURY OF THE SUPRASCAPULAR NERVE IN HORSE (SWEENY)

Joandes Henrique Fontequê<sup>1</sup>  
Anderson Fernando de Souza<sup>2</sup>  
Thiago Rinaldi Muller<sup>1</sup>  
Jackson Schade<sup>3</sup>  
Paulo Eduardo Ferian<sup>1</sup>

### ABSTRACT

This is a case report of atrophy of the shoulder muscles (sweeny) – supra and infraspinatus due to suprascapular nerve injury in a horse, cross breed, male, with 15 years of age, weigh 350 kg, used for traction, seen at the Veterinary Hospital (HCV) from the Santa Catarina State University (UDESC), Agroveterinary Sciences Center (CAV) from Lages, SC, Brazil. The animal showed clinical signs such as muscle atrophy of the scapular region and moderate instability of the shoulder joint of the left forelimb. Due to chronic and irreversible changes in the musculature, with no further complications to the animal, treatment was based on reducing workload and suitability of tack used in the animal. This is the first clinical description in Brazil of atrophy of the supra and infraspinatus muscles due to injury of the suprascapular nerve with chronic presentation.

**Keywords:** sweeny, muscle atrophy, suprascapular nerve, horse.

## ATROFIA DOS MÚSCULOS SUPRA E INFRA ESPINHOSO POR LESÃO DO NERVO SUPRAESCAPULAR EM EQUINO (SWEENY)

### RESUMO

Relata-se um caso de atrofia dos músculos supra e infraespinhoso por lesão do nervo supraescapular comumente denominada “Sweeny”, em um equino, mestiço, macho, castrado, de 15 anos de idade, pesando 350 kg, utilizado para tração, atendido no Hospital de Clínicas Veterinárias (HCV) do Centro de Ciências Agroveterinárias (CAV) da Universidade do Estado de Santa Catarina (UDESC), Lages, SC, Brasil. O animal apresentava como sinais clínicos a atrofia muscular da região delimitada pelos músculos que preenchem as fossas escapulares e moderada instabilidade da articulação escapulo umeral do membro torácico esquerdo, constatado durante inspeção em movimento. Devido à cronicidade, as alterações irreversíveis na musculatura e ao quadro estável, não trazendo maiores prejuízos ao animal, optou-se por não instaurar qualquer tratamento e recomendou-se ao proprietário a redução da carga de trabalho e adequação do arreamento utilizado no animal. Trata-se da primeira descrição clínica no Brasil de atrofia dos músculos supra e infraespinhoso por lesão ao nervo supraescapular de evolução crônica em equino.

**Palavras-chave:** sweeny, atrofia muscular, nervo supraescapular, equino.

<sup>1</sup> Professor Doutor, Centro de Ciências Agroveterinárias, Universidade do Estado de Santa Catarina (UDESC), Lages, SC.

<sup>2</sup> Departamento de Medicina Veterinária, Centro de Ciências Agroveterinárias (CAV), Universidade do Estado de Santa Catarina (UDESC). Clínica Médica de Grandes Animais. Correspondência.

<sup>3</sup> Programa de Pós Graduação em Ciência Animal, Centro de Ciências Agroveterinárias (CAV), Universidade do Estado de Santa Catarina (UDESC), Lages, SC

## ATROFIA DE LOS MÚSCULOS SUPRA Y INFRASPINOSO DEBIDO LESIONES EN EL NERVI SUPRAESCAPULAR EN EQUINO (SWEENY)

### RESUMEN

Se presenta un caso de atrofia de los músculos supra y infraespinosos por el daño del nervio supraescapular comúnmente llamado "Sweeny" en un caballo, mestizo, macho, castrado, de 15 años de edad, con un peso de 350 kg, que se utiliza para la tracción, asistimos en el Hospital Clínicas veterinarias (HCV) de Centro de Ciencias Agroveterinarias (CAV) de la Universidad del Estado de Santa Catarina (UDESC), Lages, SC, Brasil. El animal mostró signos clínicos tales como la atrofia muscular de la región limitada por los músculos que se llenan los tanques de la escápula y la inestabilidad moderada de la articulación del hombro del húmero de la extremidad anterior izquierda, que se encuentran en movimiento durante la inspección. Debido a los cambios crónicos e irreversibles en la musculatura y estable, no traen más daño al animal, se decidió no iniciar ningún tratamiento y recomendó al propietario reduce la carga de trabajo y la adecuación de guarnicionería utilizado en el animal. Esta es la primera discreción clínica en Brasil atrofia de la lesión muscular arriba y infraespinoso al nervio supraescapular con evolución crónica en equinos.

**Palabras clave:** sweeny, atrofia muscular, nervio supraescapular, equino.

### INTRODUCTION

Peripheral nerves are susceptible to the onset of trauma, due to compressive, stretching and avulsion forces leading to incomplete or complete interruption of nerve impulses, resulting in decreased or lack of sensitivity and/or motor function of the innervated region (1). The atrophy of certain muscle group is the main clinical sign observed in the neuropathies of neural motors branches. Suprascapular nerve dysfunction is associated with atrophy of the muscles of the scapular (shoulder) region, and more precisely to the supra and infraspinatus muscles, promoting instability of the shoulder joint in horses. This disease is also called sweeny (2,3,4). The susceptibility of injury of this nerve can be attributed to its anatomical location, so that cranial trauma on the brachial region can be extremely harmful (4).

Sweeny is a rare condition without predisposition of gender, breed or age (3). The present report aims to describe the first case of atrophy of the supra and infraspinatus muscles due to suprascapular nerve injury by a chronic injury in horse from Lages, State of Santa Catarina, Brazil.

### CASE REPORT

A horse, male, crossbreed, 15 year old gelding, weight 350 kg, used for traction, was admitted in the Veterinary Hospital (HCV) from the Santa Catarina State University (UDESC) from Lages, SC, Brazil. The owner had recently purchased the animal not knowing about the past history of the animal. Physical examination revealed muscular atrophy of the scapular region of the left forelimb, no recent history. The infra and suprascapular fossas were evident with clear demarcation of the scapular spine (Figure 1 A, B and C). The animal did not show any change on physical examination, except for muscle atrophy. In specific examination of the musculoskeletal system, through inspection at rest no swelling, scarring or alopecia throughout the length of the member was identified. No presence of pain or sensitivity to palpation was observed. Motion inspection revealed moderate abduction of the scapulohumeral of the left forelimb. The flexion tests performed were negative.

The diagnosis of suprascapular nerve injury was made based on location of the muscle atrophy and altered motion pattern without pain or alternative systemic source for the atrophy. Even having no associated history reported by the owner, there was inadequate tack with support point just above the shoulder joint, concurring with nerve topography. Because it is a chronic condition in which there was adaptation and compensation, not bringing further damage to the animal, no treatment was performed, since the most effective option in this case would be a surgical investigation in order to confirm possible injury or compressive agent.

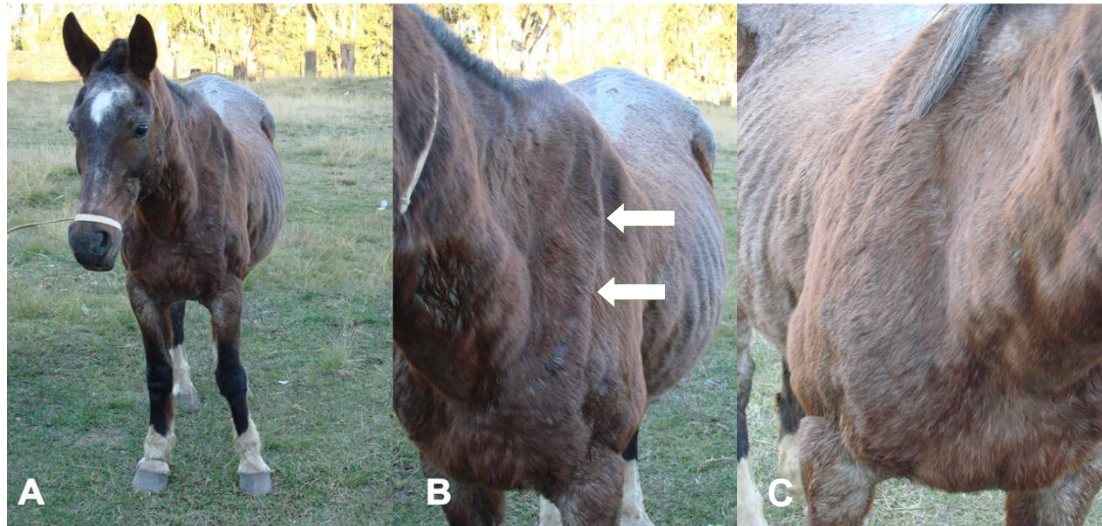


Figure 1. Equine, cross breed, 15 year old gelding used for traction work with atrophy of the infra and supraespinatus muscles with evident scapular spine (arrows) (A and B). Contralateral forelimb with normal musculature of the scapular region (C).

## DISCUSSION AND CONCLUSION

The first observations of atrophy of the scapular muscles occurred in animals used for traction, mainly due to the inappropriate use of tacks, especially those shaped collar like, so that the intense and prolonged contact on the cranial region of the scapula would eventually promote friction and consequent injury (5). Currently this condition is linked to situations where the animal suffers excessive and/or violent retraction of the member or any direct trauma to the brachial region (3).

The main clinical sign in this condition is the atrophy of the muscles overlying the scapula. Low lameness may reflect muscle atrophy due to the support in the limb insufficiency, in which case we also observed reduction in muscle mass of the triceps. Fractures of the scapula, humerus, biceps bursitis, osteoarthritis and osteochondrosis of the shoulder joint, among other causes may mimic similar clinical and pathologic signs (6).

Intense lameness is seen in acute events, so the disease progresses and the animal consistently supports in the limb, or in those situations where a chronic process is established, there is lateral displacement of the humeral shoulder joint. This instability is due to the biomechanical malfunction of infra and supraespinatus muscles that act as stabilizers of the joint are as well as the collateral ligaments.

According to Dyce et al. (7), Getty et al. (8) the predisposition of the injury of the suprascapular nerve is its anatomical location. The nerve usually originates from the convergence of branches from the sixth and seventh cervical vertebrae components of the

brachial plexus, following a proximal to the medial aspect of this scapular region to a more lateral direction between supraespinatus and subscapularis muscles ensuing the suprascapular artery, bypassing the cranial neck of the scapula, about seven inches above the supraglenoid tuber and then reaches the distal end of supraespinous fossa, in which reaches the shoulder muscles.

Precisely at the time that the nerve travels from medial to lateral in the member, one small strip of tendon overlies the nerve and the muscle provides considerable coverage with the subclavius and supraspinatus muscles, which exert pressure on the cranial border of the scapular notch. There is no significant interstitial tissue between the nerve and scapula in the region, which could have a damping function, leaving it vulnerable to trauma. Histologically, it was observed in animals without clinical signs, some demyelination process to a chronic level of the nerve, this suggests that there is a natural anatomical condition in which exerts chronic nerve compression, but with only subclinical implications which would make it more vulnerable to acute trauma, or even the appearance of clinical signs without a history of trauma nerve (9).

As proposed by Stashak (3), surgical treatment is advised when preceded the failure of conservative treatment after 10 to 12 weeks. This relates to the time rate of peripheral axonal growth that is 1mm/day, depending on the extent of supraescapular nerve which usually occurs somewhere around 7-8cm. The removal of a wedge-shaped piece of the cranial border of the scapula in the area where the nerve pierces can be beneficial as the pressure relief and reestablishment of innervation. In the long term, there is no significant difference in conservatively treated horses to those who underwent surgical exploration and resection of a scapular notch (2).

Conservative treatment is generally based on repose for a sufficiently long period with systemically therapy with nonsteroidal anti-inflammatory drugs (NSAID's), daily showers with cold water and/or compression and topical anti-inflammatory products such as dimethyl sulfoxide (DMSO) (3,10). The regeneration of injured nerve fibers is influenced by numerous factors such as the nature and level of the lesion, denervation time, type and diameter of nerve fibers affected, the individual's age and other individual variables. Another problem observed in chronic cases is the establishment of irreversible changes in muscle tissue by replacement of fibrous tissue in cases of neurogenic muscular atrophy (3).

The diagnosis was based on standard topographic and location of the muscle atrophy, in which only the supra and infraespinatus muscles presented atrophy. This is due to the fact that the suprascapular nerve function is to provide motor innervation of these muscles. Electromyography is described as a diagnostic tool and should be performed with at least seven days after the injury (11). Surgical exploration of the region could be beneficial to elucidate the possible cause of compression, but would not produce a significant effect on the recovery of the muscle, since the time of disuse presents a degree of irreversible degeneration of muscle fibers with replacement by connective and adipose tissue.

Literature regarding regeneration of nerve tissue proposes therapies that have satisfactory results experimentally. Conservative and surgical treatments are described with variables clinical outcomes (10,12,13). Literature suggest physiotherapy alone or combined with drug therapy to be more effective for functional recovery (14).

To date, this is the first report of Sweeny in Brazil, but not necessarily indicates an unusual and unprecedented condition but perhaps a mere oversight and / or inattention to the diagnosis, since the large number of horses that are used for traction and are subject to this condition. Veterinarians should be aware of sweeny and include on the list of differential diagnoses in cases of muscular atrophy of the scapular region.

**REFERENCES**

1. Monte-Raso VV, Barbieri CH, Mazzer N, Fazan VPS. Os efeitos do ultra-som terapêutico nas lesões por esmagamento do nervo ciático de ratos: análise funcional da marcha. *Rev Bras Fisioter.* 2006;10(1):113-9.
2. Mayhew J. *Large animal neurology.* 2nd ed. Oxford: Wiley-Blackwell; 2009.
3. Stashak TS. Lesão do nervo supra-escapular (Sweeny). In: Stashak TS. *Claudicação em equinos segundo Adams.* 5a ed. São Paulo: Roca; 2006. p.864-7.
4. Adams OR. Atrophy of the supraspinatus and infraspinatus muscles (Sweeny). In: Adams OR. *Lameness in horse.* 3rd ed. Philadelphia: Lea e Febiger; 1974. p.162-3.
5. Furr M. Disorders of the peripheral nervous system. In: Furr M, Reed S. *Equine neurology.* Iowa: Blackwell Publishing; 2008. p.331-2.
6. Carmona JU, López C. Autologous platelet concentrates as a treatment for shoulder injury in a horse. *J Equine Vet Sci.* 2011;31(9):506-10.
7. Dyce KM, Wensing CJG, Sack WO. *Tratado de anatomia veterinária.* 3a ed. Rio de Janeiro: Elsevier; 2004.
8. Getty R, Rosenbaum CE, Ghoshal NG, Hillmann D. Sisson e Grossman: *anatomia dos animais domésticos.* Rio de Janeiro: Guanabara Koogan; 1986.
9. Duncan ID, Schneider RK, Hammang JP. Subclinical entrapment neuropathy of the equine suprascapular nerve. *Acta Neuropathol.* 1987;74(1):53-61.
10. Dutton DM, Honnas CM, Watkins JP. Non-surgical treatment of suprascapular nerve injury in horses: 8 cases (1988-1998). *J Am Vet Med Assoc.* 1999;214(11):1657-9.
11. Baxter GM. *Manual of equine lameness.* Oxford: John Wiley and Sons; 2011.
12. Adams OR, Schneider RK, Bramlage LR, Easley KJ, Schneider JE. A surgical approach to treatment of suprascapular nerve injury in the horse. *J Am Vet Med Assoc.* 1985;187(10):1016-8.
13. Schneider JE, Adams OR, Easley KJ, Schneider RK, Bramlage LR, Peter J, et al. Scapular notch resection for suprascapular nerve decompression in 12 horses. *J Am Vet Med Assoc.* 1985;187(10):1019-20.
14. Rattenhuber S, Benz H, Gajewski Z, Carstanjen B. Swim training as therapy of neurogenic induced unilateral shoulder instability in three horses. *Pferdeheilkunde.* 2012;28(6):665-7.

**Recebido em: 08/05/2016****Aceito em: 10/02/2017**